

Research Article

Detection of Mullerian Duct Anomalies: Diagnostic Utility of Two-Dimensional Ultrasonography as Compared to MRI

Dr. M. S. Hemhnath¹, Dr. E. M. Aarathi²

¹Associate Professor, Department of RadioDiagnosis, Venkateswara Medical College, India.

²Assistant Professor, Department of Obstetrics & Gynaecology, Madha Medical College, No 49, VV Koil Street, Choolai, Chennai-600112, India.

*Corresponding Author

Dr. E. M. Aarathi, Assistant Professor, Department of Obstetrics & Gynaecology, Madha Medical College, No 49, VV Koil Street, Choolai, Chennai-600112, India.

Email:

aarathimohan95@gmail.com

Article History

Received: 16-03-2026

Revised: 12.04.2026

Accepted: 26.04.2026

Published: 15.05.2026

Citations:

Hemhnath, M. S., & Aarathi, E. M. (Year). Detection of Mullerian duct anomalies: Diagnostic utility of two-dimensional ultrasonography as compared to MRI. *J Surg Radiol*, V5(5) 118-125

Abstract: **Introduction:** Müllerian duct anomalies (MDAs) are congenital malformations arising from abnormal embryological development, fusion, or resorption of the Müllerian ducts. These abnormalities, which impact the uterus, cervix, fallopian tubes, and upper vagina, are frequently linked to pelvic discomfort, irregular menstruation, infertility, and unfavorable obstetric outcomes. Appropriate clinical care and surgical planning depend on an early and precise diagnosis. Imaging is essential to the assessment of MDAs. While magnetic resonance imaging (MRI) offers better soft tissue resolution and multiplanar visualization, two-dimensional ultrasonography (2D USG) is frequently utilized as the first-line imaging modality due to its affordability and accessibility. **Objectives:** To compare the diagnostic utility of two-dimensional ultrasonography with magnetic resonance imaging in detecting and classifying Müllerian duct anomalies. **Materials and Methods:** This prospective observational study was conducted on 60 patients clinically suspected to have Müllerian duct anomalies. Following a thorough pelvic examination, each patient had an MRI and 2D ultrasound. When available, imaging results were compared to the reference standard—operative, hysteroscopic, or laparoscopic findings. For both imaging modalities, the following metrics were computed: sensitivity, specificity, positive predictive value, negative predictive value, and overall diagnostic accuracy. **Results:** The most common presenting complaints were infertility and recurrent pregnancy loss. MRI demonstrated superior diagnostic performance compared to 2D ultrasonography. The sensitivity, specificity, and diagnostic accuracy of MRI were 95%, 93%, and 94%, respectively, whereas 2D ultrasonography demonstrated sensitivity of 78%, specificity of 85%, and accuracy of 81%. MRI was particularly effective in differentiating septate uterus from bicornuate uterus and in identifying associated cervical and vaginal anomalies. **Conclusion:** MRI is highly accurate and reliable for the evaluation and classification of Müllerian duct anomalies and should be considered the gold standard imaging modality. However, 2D ultrasonography remains a valuable and cost-effective screening tool for initial assessment.

Keywords: Müllerian duct anomalies, ultrasonography, MRI, congenital uterine anomalies, septate uterus, bicornuate uterus

INTRODUCTION

Müllerian duct anomalies (MDAs) are congenital malformations of the female reproductive tract resulting from abnormal embryological development of the paired Müllerian ducts during fetal life. Defects in the Müllerian ducts' organogenesis, fusion, canalization, or resorption between the sixth and twenty-second weeks of pregnancy cause these abnormalities.^[1] The fallopian tubes, uterus, cervix, and upper two-thirds of the vagina are typically formed from the Müllerian ducts. A wide range of uterine abnormalities with different clinical consequences might result from any disruption in their development.^[2]

The incidence of Müllerian duct abnormalities is reported to be between 0.5% to 5% in the general female population, but it is much greater in women who have infertility, repeated pregnancy loss, or obstetric problems.^[3] Research has shown that prevalence rates can reach 25% in women who experience repeated miscarriages and about 10% in those who are infertile. Because many women are asymptomatic and go

undetected until reproductive issues emerge, the real prevalence may be underestimated. Because Müllerian duct defects are linked to a number of gynecological and obstetric issues, such as infertility, recurrent spontaneous abortions, premature labor, malpresentation, dysmenorrhea, pelvic discomfort, endometriosis, and irregular uterine bleeding, they are clinically significant.^[5] Certain anomalies, such as septate uterus, have particularly poor reproductive outcomes if untreated. Timely diagnosis and appropriate management can significantly improve fertility and pregnancy outcomes.^[6]

To classify Müllerian duct abnormalities, a number of categorization schemes have been put forth. One of the most popular classification schemes is still the American Society for Reproductive Medicine (ASRM) system.^[7] Hypoplasia/agenesis, unicornuate uterus, didelphys uterus, bicornuate uterus, septate uterus, arcuate uterus, and diethylstilbestrol-related malformations are the seven main categories into which it divides anomalies. A more current categorization scheme was put out by the European Society of Human Reproduction and

Embryology (ESHRE) with the goal of enhancing uniformity and decreasing uncertainty.^[8] Because treatment approaches vary depending on the kind of abnormality, accurate diagnosis and categorization of MDAs are crucial. For instance, septate uteruses are frequently treated hysteroscopically, but bicornuate uteruses may only sometimes need metroplasty.^[9] Inappropriate therapy and unfavorable reproductive results might result from misdiagnosis. When diagnosing Müllerian abnormalities, imaging is crucial. Hysterosalpingography (HSG) has historically been used extensively to assess abnormalities in the uterine cavity; however, it offers little information on the exterior shape of the uterus and related extrauterine defects.^[10] The identification and description of uterine abnormalities have been greatly enhanced by developments in imaging methods. When a patient is suspected of having Müllerian abnormalities, two-dimensional ultrasonography (2D USG) is typically the first imaging modality used. It is broadly accessible, low-cost, noninvasive, and radiation-free.^[11] Information on uterine morphology, the structure of the endometrial cavity, and related adnexal disease can be obtained using transabdominal and transvaginal ultrasound. However, because of limited vision of the exterior uterine contour, 2D ultrasonography is limited in its ability to reliably differentiate complicated irregularities.^[12] Although three-dimensional ultrasonography has become a better method for evaluating the uterus, its accessibility is still restricted in many institutions, particularly in settings with minimal resources.^[13] As a result, 2D ultrasonography is still often employed as the main diagnostic method in standard clinical practice. For the assessment of Müllerian duct abnormalities, magnetic resonance imaging (MRI) is now considered the gold standard imaging technique.^[14] Excellent soft tissue contrast, multiplanar imaging capabilities, and a thorough evaluation of the interior and exterior uterine architecture are all provided by MRI. Additionally, it allows for the simultaneous assessment of related pelvic and renal abnormalities, which are often linked to Müllerian malformations.^[15] MRI is especially helpful in distinguishing between bicornuate and septate uteruses, a feature with significant therapeutic significance.^[16] The diagnostic precision of MRI and ultrasound in assessing uterine abnormalities has been examined in a number of investigations. Troiano and McCarthy showed that MRI's better vision of uterine anatomy allows it to characterize Müllerian abnormalities with almost 100% accuracy.^[17] MRI is also very useful for assessing complicated uterine anomalies and related pelvic abnormalities, according to Bermejo et al.^[18] Because of its accessibility, cost, and convenience, ultrasonography is still frequently used despite MRI's greater diagnostic capabilities. Due to financial limitations and inadequate infrastructure, MRI may not always be easily accessible in underdeveloped nations.^[19] In order to guide imaging procedures, it is crucial to comprehend the relative diagnostic performance of 2D ultrasonography in comparison to MRI.

The goal of the current investigation was to evaluate the diagnostic value of MRI and two-dimensional ultrasonography in identifying Müllerian duct abnormalities. Using surgical or hysteroscopic results as the reference standard, the study sought to assess the sensitivity, specificity, and overall accuracy of both methods.^[20]

AIMS AND OBJECTIVES

Aim

To evaluate and compare the diagnostic utility of two-dimensional ultrasonography and magnetic resonance imaging in the detection and classification of Müllerian duct anomalies.

Objectives

1. To identify various types of Müllerian duct anomalies in clinically suspected patients.
2. To assess the sensitivity and specificity of 2D ultrasonography in diagnosing MDAs.
3. To evaluate the diagnostic accuracy of MRI in classification of MDAs.
4. To compare imaging findings with operative or hysteroscopic findings.
5. To determine the role of MRI as a confirmatory imaging modality following ultrasonography.

MATERIALS AND METHODS

Study Design

This was a prospective observational study.

Study Setting

The study was conducted in the Department of Radiodiagnosis in collaboration with the Department of Obstetrics and Gynecology at a tertiary care teaching hospital.

Study Duration

The study was conducted over a period of 18 months.

Study Population

A total of 60 female patients clinically suspected to have Müllerian duct anomalies were included in the study.

Inclusion Criteria

- Patients with primary infertility
- Patients with recurrent pregnancy loss
- Patients with menstrual abnormalities
- Patients with suspected uterine anomalies on clinical examination
- Patients willing to participate in the study

Exclusion Criteria

- Patients with contraindications to MRI
- Pregnant patients
- Patients with previous uterine surgery altering uterine morphology
- Patients unwilling to provide consent

PROCEDURE OF STUDY

All patients underwent detailed clinical history and gynecological examination. Relevant demographic details including age, presenting complaints, obstetric history, menstrual history, and infertility status were recorded.

Ultrasonography Examination

All patients initially underwent pelvic ultrasonography using high-resolution ultrasound machines equipped with transabdominal and transvaginal probes. Sagittal and transverse plane scans were performed on the patients. Adnexal anomalies, myometrial morphology, uterine size, shape, endometrial cavity architecture, and related pelvic pathology were assessed. Findings suggestive of Müllerian anomalies such as duplication of uterine cavity, abnormal fundal contour, uterine septum, or uterine asymmetry were documented.

MRI Examination

Subsequently, all patients underwent MRI examination using a 1.5 Tesla MRI scanner. Axial, sagittal, and coronal T1-weighted and T2-weighted images of the pelvis were obtained. MRI findings regarding uterine

morphology, external fundal contour, internal cavity anatomy, cervical duplication, vaginal septum, and associated renal anomalies were analyzed.

MRI findings were classified according to the ASRM classification system.

Reference Standard

Operative findings obtained during laparoscopy, hysteroscopy, or combined surgical procedures were considered the reference standard wherever available.

STATISTICAL ANALYSIS

Data were entered into Microsoft Excel and analyzed using Statistical Package for Social Sciences (SPSS) software version 25.0. Categorical variables were expressed as frequencies and percentages. Sensitivity, specificity, positive predictive value (PPV), negative predictive value (NPV), and overall diagnostic accuracy were calculated for both 2D ultrasonography and MRI. The Chi-square test was used to compare diagnostic performance between imaging modalities. A p-value less than 0.05 was considered statistically significant.

RESULTS

Table 1: Distribution of Patients According to Age Group

Age Group (Years)	Number of Patients	Percentage (%)
15–20	6	10.0
21–25	18	30.0
26–30	22	36.7
31–35	10	16.7
>35	4	6.6
Total	60	100

Table 1 shows the age-wise distribution of patients included in the study. With 22 instances (36.7%), the age group of 26–30 years old accounted for the majority of patients, followed by the age group of 21–25 years old with 18 cases (30.0%). Ten patients (16.7%) were between the ages of 31 and 35, while six patients (10.0%) were between the ages of 15 and 20. Of the patients, only 4 (6.6%) were above 35. The results show that women of reproductive age, especially those between the ages of 21 and 30, were most frequently found to have Müllerian duct abnormalities.

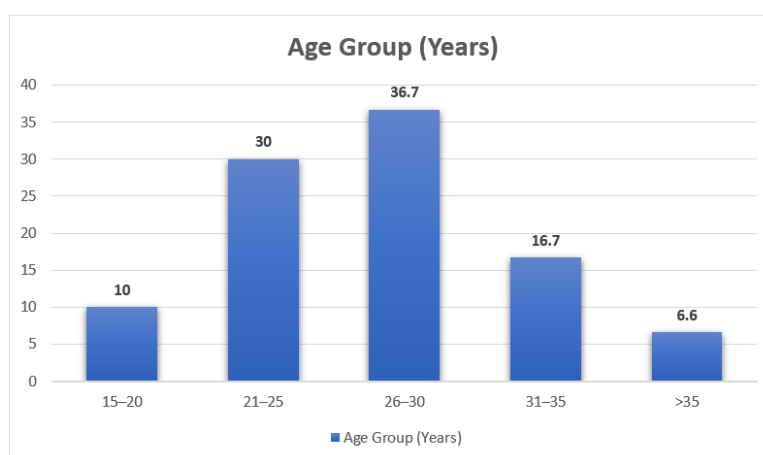


Figure 1: Age Distribution

Table 2: Clinical Presentation of Patients

Clinical Presentation	Number of Patients	Percentage (%)
Primary infertility	24	40.0
Recurrent pregnancy loss	18	30.0
Dysmenorrhea	8	13.3
Pelvic pain	6	10.0
Menstrual irregularities	4	6.7
Total	60	100

Table 2 illustrates the clinical presentation of patients with suspected Müllerian duct anomalies. Primary infertility was the most common presenting complaint, observed in 24 patients (40.0%), followed by recurrent pregnancy loss in 18 patients (30.0%). Eight patients (13.3%) had dysmenorrhea, while six patients (10.0%) had pelvic discomfort. The least frequent manifestation, observed in 4 individuals (6.7%), was irregular menstruation. These results show that the most common clinical signs of Müllerian duct defects were reproductive issues, namely infertility and repeated miscarriages.

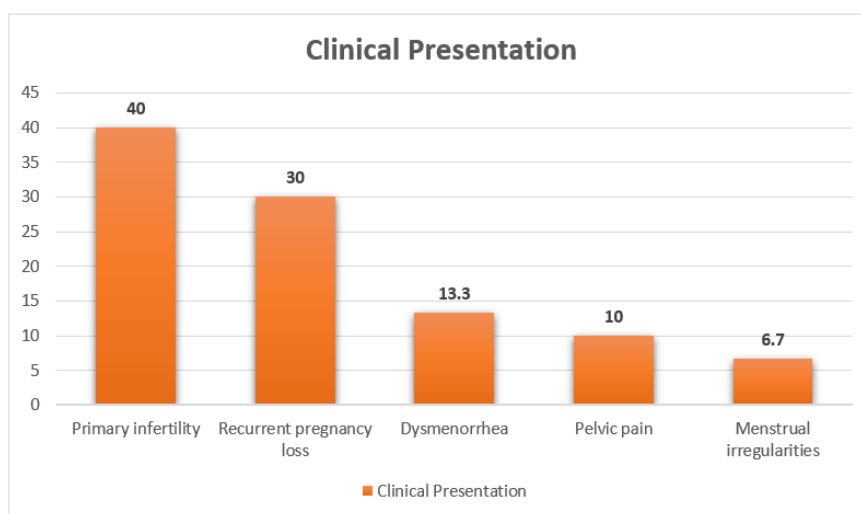


Figure 2: Clinical Presentation of Patients

Table 3: Types of Müllerian Duct Anomalies Detected on MRI

Type of Anomaly	Number of Patients	Percentage (%)
Septate uterus	18	30.0
Bicornuate uterus	14	23.3
Unicornuate uterus	8	13.3
Uterus didelphys	7	11.7
Arcuate uterus	5	8.3
Agenesis/Hypoplasia	4	6.7
Others	4	6.7
Total	60	100

Table 3 depicts the distribution of various Müllerian duct anomalies detected on MRI. With 18 patients (30.0%), septate uterus was the most often seen abnormality. The second most prevalent defect, seen in 14 cases (23.3%), was a bicornuate uterus. Eight patients (13.3%) had unicornuate uteruses, while seven patients (11.7%) had uterine didelphys. Five instances (8.3%) had an arcuate uterus. Four instances (6.7%) each were caused by agenesis/hypoplasia and other uncommon abnormalities. The findings show that the majority of Müllerian duct abnormalities in the current study were septate and bicornuate uteruses.

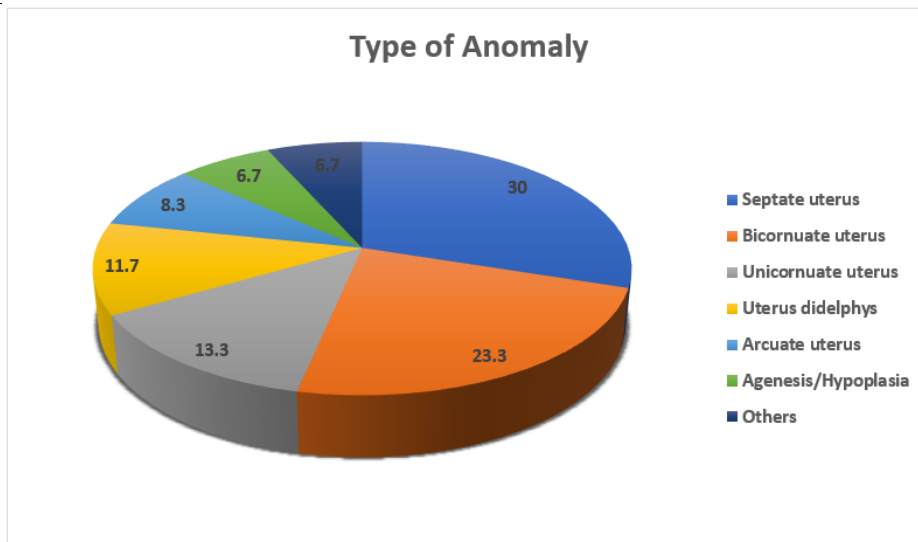


Figure 3: Types of Müllerian Duct Anomalies Detected on MRI

Table 4: Comparison of Diagnostic Performance of 2D USG and MRI

Modality	Sensitivity (%)	Specificity (%)	Accuracy (%)
2D Ultrasonography	78	85	81
MRI	95	93	94

Table 4 compares the diagnostic performance of two-dimensional ultrasonography and MRI in detecting Müllerian duct anomalies. With 95% sensitivity, 93% specificity, and 94% total diagnostic accuracy, MRI showed exceptional diagnostic effectiveness. By contrast, 2D ultrasonography demonstrated diagnostic accuracy of 81%, specificity of 85%, and sensitivity of 78%. These results imply that, while ultrasonography is still a helpful first screening technique, MRI is substantially more accurate than 2D ultrasonography in the assessment and categorization of Müllerian duct abnormalities.

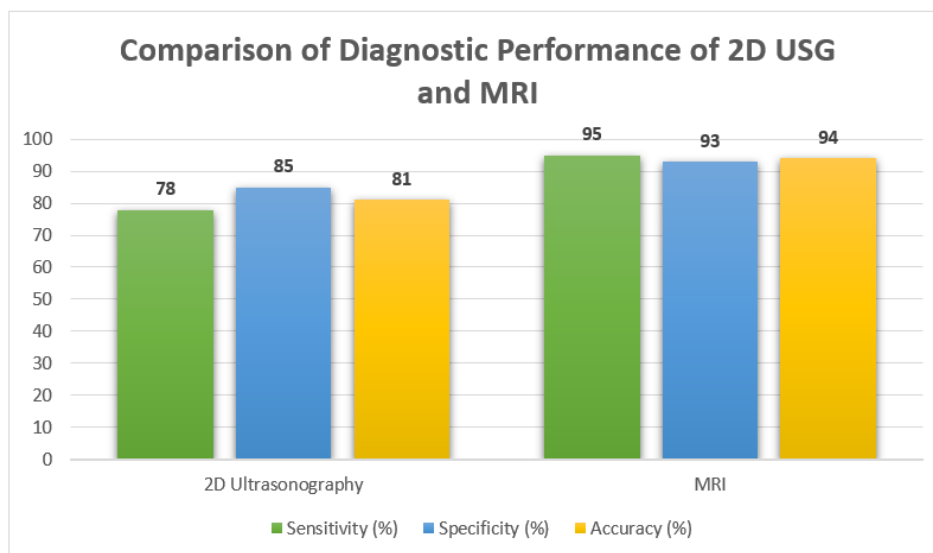


Figure 4: Comparison of Diagnostic Performance of 2D USG and MRI

DISCUSSION

The present study was conducted to evaluate the diagnostic utility of two-dimensional ultrasonography (2D USG) compared with magnetic resonance imaging (MRI) in the detection and classification of Müllerian duct anomalies (MDAs). The current study's results are examined below in light of earlier published works. The age group of 26–30 years old accounted for 36.7% of the

study population in the current study (Table 1), followed by the age group of 21–25 years old with 30% of patients. 16.7% of patients were between the ages of 31 and 35, whereas only 10% were between the ages of 15 and 20 and 6.6% were older than 35. The clinical relevance of Müllerian duct anomalies throughout the reproductive years is reflected in the preponderance of patients in the reproductive age range, especially when women seek medical assessment for infertility, repeated miscarriages,

or irregular menstruation. These results are in line with Saravelos et al.'s findings that congenital uterine abnormalities are frequently identified during infertility workup or assessment for unfavorable reproductive outcomes.^[3]

Similarly, Grimbizis et al. noted that while reproductive issues become more noticeable in the second and third decades of life, the majority of women with Müllerian malformations appear during this time.^[1] While older women are frequently identified after many obstetric failures, younger individuals may remain asymptomatic until menarche or marriage.

Reduced reproductive consultations at older ages or delayed diagnosis in asymptomatic persons might account for the study's comparatively smaller number of participants over 35. Furthermore, primary amenorrhea or cyclic pelvic discomfort are often the first signs of serious abnormalities such as uterine agenesis or obstructive deformities.^[21] The current study's age distribution emphasizes how crucial it is to keep a high index of suspicion for Müllerian defects in women of reproductive age who report with infertility or repeated miscarriages. According to Table 2, primary infertility accounted for 40% of patients' presenting complaints, with recurrent pregnancy loss coming in second at 30%. Menstrual abnormalities, pelvic discomfort, and dysmenorrhea made up 6.7%, 10%, and 13.3% of the cases, respectively. The current study's findings on the significant frequency of infertility among patients with Müllerian duct abnormalities are consistent with earlier findings. Pregnancy maintenance, embryo development, and implantation are all known to be hampered by congenital uterine defects.^[22] In particular, a septate uterus is linked to poor septal vascularization, which can result in repeated miscarriages and implantation failure.^[6]

According to Acien, uterine abnormalities are far more prevalent in infertile women than in the general population.^[4] In a similar vein, Propst and Hill discovered that congenital uterine anomalies were significantly more common in women who had repeated pregnancy loss.^[20]

The second most frequent presentation in the current research was recurrent pregnancy loss. This result is consistent with research showing a substantial correlation between septate and bicornuate uteri and fetal malpresentation, premature labor, and spontaneous abortions.^[5] Fetal development and pregnancy continuation are negatively impacted by the aberrant uterine cavity and decreased uterine volume in these defects.

A subgroup of individuals also had pelvic discomfort and dysmenorrhea. These symptoms are most prevalent in obstructive Müllerian abnormalities, such as transverse vaginal septum or unicornuate uterus with noncommunicating rudimentary horn.^[15] Because most abnormalities primarily influence reproductive outcomes rather than menstrual physiology, menstrual irregularities were comparatively less prevalent in the current research. The results highlight that the most

significant clinical signs that induce radiographic assessment for Müllerian abnormalities are still infertility and recurrent pregnancy loss. According to Table 3, the most frequent Müllerian aberration found on MRI was septate uterus (30% of cases), which was followed by bicornuate uterus (23.3%), unicornuate uterus (13.3%), uterine didelphys (11.7%), arcuate uterus (8.3%), and agenesis/hypoplasia (6.7%).

According to the literature, septate uterus is thought to be the most common Müllerian defect, which is compatible with the prevalence of septate uterus in our study.^[18] Troiano and McCarthy also noted that the most frequent defect seen during imaging examination was a septate uterus.^[2] Although hysteroscopic septal excision may be able to treat a septate uterus, it is clinically significant since it is linked to poor reproductive results. Thus, it is crucial to accurately distinguish from a bicornuate uterus.^[23] The second most prevalent aberration in the current investigation was a bicornuate uterus. Preterm labor, malpresentation, and repeated pregnancy loss are linked to this defect, which is caused by inadequate fusion of the Müllerian ducts.^[19]

When it came to detecting complicated abnormalities like uterine didelphys and unicornuate uterus, MRI proved to be a very useful tool. MRI's superior soft tissue contrast and multiplanar imaging capabilities enable accurate evaluation of the cervix, vagina, external fundal contour, and uterine morphology.^[14] The relevance of MRI in assessing congenital absence or underdevelopment of reproductive organs is highlighted by the finding of agenesis/hypoplasia in 6.7% of individuals. Because MRI properly depicts pelvic architecture and related renal abnormalities, it is especially useful in individuals with primary amenorrhea.^[15] The results of this study corroborate those of earlier research by Bermejo et al., which showed that MRI was superior for the categorization and characterisation of Müllerian abnormalities.^[10]

The diagnostic capabilities of MRI and 2D ultrasound are contrasted in Table 4. In comparison to 2D ultrasonography, which showed sensitivity of 78%, specificity of 85%, and accuracy of 81%, MRI in this study revealed much greater sensitivity (95%), specificity (93%), and total correctness (94%). The capacity of MRI to provide multiplanar images with exceptional soft tissue resolution is responsible for the better diagnostic performance seen in this investigation. For the purpose of classifying Müllerian abnormalities, MRI properly assesses the exterior fundal contour as well as the inside uterine cavity.^[17] Despite being widely accessible and reasonably priced, two-dimensional ultrasonography has certain drawbacks. Because evaluation of the exterior uterine shape is frequently insufficient, it may be unable to distinguish between septate and bicornuate uteruses.^[11]

MRI exhibited the best diagnosis accuracy for Müllerian abnormalities, according to Pellerito et al.'s comparison of MRI, ultrasonography, and hysterosalpingography.^[10] Carrington et al. published similar results, showing that MRI sensitivity in characterizing uterine abnormalities

exceeded 90%.^[14] Because ultrasonography is inexpensive, accessible, and noninvasive, it is nevertheless a crucial first-line examination despite its decreased accuracy. While MRI is only used for confirmation and in-depth characterisation, ultrasonography is a useful screening technique in situations with limited resources.^[13] The current study indicates that magnetic resonance imaging (MRI) is the gold standard for evaluating Müllerian duct abnormalities and should be employed anytime accurate categorization is needed for surgical or therapeutic therapy.

CONCLUSION

The present study highlights the significant role of imaging in the diagnosis and classification of Müllerian duct anomalies (MDAs), which are important causes of infertility, recurrent pregnancy loss, menstrual disturbances, and adverse obstetric outcomes. The impact of these congenital abnormalities on reproduction was highlighted by the fact that the majority of patients in this research were women of reproductive age who mostly presented with infertility and recurrent pregnancy loss. The most prevalent form of anomaly seen was a septate uterus. With greater sensitivity, specificity, and overall diagnostic accuracy, MRI outperformed two-dimensional ultrasonography in terms of diagnostic performance. MRI was especially useful in distinguishing between septate and bicornuate uteruses because it offered superior delineation of uterine morphology, external fundal contour, and related cervical or vaginal abnormalities. Because these abnormalities have quite diverse therapy approaches, accurate distinction is crucial from a clinical standpoint. Due to its widespread availability, noninvasiveness, affordability, and convenience of use, 2D ultrasonography is still a useful first screening modality even if its diagnostic accuracy was somewhat lower. As a result, while MRI should be regarded as the gold standard confirmatory imaging modality for accurate evaluation and categorization of Müllerian duct abnormalities, ultrasonography can be used effectively as a first-line examination.

LIMITATIONS OF THE STUDY

1. The study was conducted at a single tertiary care center, which may limit the generalizability of the findings to the wider population.
2. The sample size of 60 patients was relatively small and may not represent the complete spectrum of Müllerian duct anomalies.
3. Surgical or hysteroscopic confirmation was not available in all patients, which could affect definitive correlation of imaging findings.
4. Three-dimensional ultrasonography, which has higher diagnostic accuracy than 2D ultrasonography, was not included in the study.

5. Interobserver variability in interpretation of imaging findings was not assessed.
6. Long-term reproductive and obstetric outcomes of patients were not evaluated in the present study.

REFERENCES

1. Grimbizis GF, Campo R, Gordts S, Brucker S, Gergolet M, Li TC, et al. Clinical approach for the classification of congenital uterine malformations. *Gynecol Surg*. 2012;9(2):119-129. doi:10.1007/s10397-011-0709-0
2. Troiano RN, McCarthy SM. Müllerian duct anomalies: imaging and clinical issues. *Radiology*. 2004;233(1):19-34. doi:10.1148/radiol.2331020777
3. Saravelos SH, Cocksedge KA, Li TC. Prevalence and diagnosis of congenital uterine anomalies in women with reproductive failure: a critical appraisal. *Hum Reprod Update*. 2008;14(5):415-429. doi:10.1093/humupd/dmn018
4. Acien P. Incidence of Müllerian defects in fertile and infertile women. *Hum Reprod*. 1997;12(7):1372-1376. doi:10.1093/humrep/12.7.1372
5. Grimbizis GF, Camus M, Tarlatzis BC, Bontis JN, Devroey P. Clinical implications of uterine malformations and hysteroscopic treatment results. *Hum Reprod Update*. 2001;7(2):161-174. doi:10.1093/humupd/7.2.161
6. Homer HA, Li TC, Cooke ID. The septate uterus: a review of management and reproductive outcome. *Fertil Steril*. 2000;73(1):1-14. doi:10.1016/S0015-0282(99)00480-1
7. The American Fertility Society. The AFS classifications of adnexal adhesions, distal tubal occlusion, tubal occlusion secondary to tubal ligation, tubal pregnancies, Müllerian anomalies and intrauterine adhesions. *Fertil Steril*. 1988;49(6):944-955. doi:10.1016/S0015-0282(16)59942-7
8. Grimbizis GF, Gordts S, Di Spiezio Sardo A, Brucker S, De Angelis C, Gergolet M, et al. The ESHRE/ESGE consensus on the classification of female genital tract congenital anomalies. *Hum Reprod*. 2013;28(8):2032-2044. doi:10.1093/humrep/det098
9. Pabuccu R, Gomel V. Reproductive outcome after hysteroscopic metroplasty in women with septate uterus and otherwise unexplained infertility. *Fertil Steril*. 2004;81(6):1675-1678. doi:10.1016/j.fertnstert.2003.10.039
10. Pellerito JS, McCarthy SM, Doyle MB, Glickman MG, DeCherney AH. Diagnosis of uterine anomalies: relative accuracy of MR imaging, endovaginal sonography, and hysterosalpingography. *Radiology*. 1992;183(3):795-800. doi:10.1148/radiology.183.3.1584930
11. Nicolini U, Bellotti M, Bonazzi B, Zamberletti D, Candiani GB. Can ultrasound be used to screen

- uterine malformations? *Fertil Steril*. 1987;47(1):89-93. doi:10.1016/S0015-0282(16)49924-8
12. Woelfer B, Salim R, Banerjee S, Elson J, Regan L, Jurkovic D. Reproductive outcomes in women with congenital uterine anomalies detected by three-dimensional ultrasound screening. *Obstet Gynecol*. 2001;98(6):1099-1103. doi:10.1016/S0029-7844(01)01638-7
13. Salim R, Woelfer B, Backos M, Regan L, Jurkovic D. Reproducibility of three-dimensional ultrasound diagnosis of congenital uterine anomalies. *Ultrasound Obstet Gynecol*. 2003;21(6):578-582. doi:10.1002/uog.157
14. Carrington BM, Hricak H, Nuruddin RN, Secaf E, Laros RK Jr, Hill EC. Müllerian duct anomalies: MR imaging evaluation. *Radiology*. 1990;176(3):715-720. doi:10.1148/radiology.176.3.2389028
15. Fedele L, Dorta M, Brioschi D, Massari C, Candiani GB. Magnetic resonance evaluation of double uteri. *Obstet Gynecol*. 1989;74(5):844-847. doi:10.1097/00006250-198911000-00027
16. Ghi T, Casadio P, Kuleva M, Perrone AM, Savelli L, Giunchi S, et al. Accuracy of three-dimensional ultrasound in diagnosis and classification of congenital uterine anomalies. *Fertil Steril*. 2009;92(2):808-813. doi:10.1016/j.fertnstert.2008.05.091
17. Troiano RN. Magnetic resonance imaging of Müllerian duct anomalies of the uterus. *Top Magn Reson Imaging*. 2003;14(4):269-279. doi:10.1097/00002142-200308000-00002
18. Bermejo C, Martínez Ten P, Cantarero R, Diaz D, Pérez Pedregosa J, Barrón E, et al. Three-dimensional ultrasound in the diagnosis of Müllerian duct anomalies and concordance with magnetic resonance imaging. *Ultrasound Obstet Gynecol*. 2010;35(5):593-601. doi:10.1002/uog.7551
19. Chandler TM, Machan LS, Cooperberg PL, Harris AC, Chang SD. Müllerian duct anomalies: from diagnosis to intervention. *Br J Radiol*. 2009;82(984):1034-1042. doi:10.1259/bjr/99354802
20. Propst AM, Hill JA. Anatomic factors associated with recurrent pregnancy loss. *Semin Reprod Med*. 2000;18(4):341-350. doi:10.1055/s-2000-13213
21. Oppelt P, Renner SP, Kellermann A, Brucker S, Hauser GA, Ludwig KS, et al. Clinical aspects of Mayer-Rokitansky-Küster-Hauser syndrome: recommendations for clinical diagnosis and staging. *Hum Reprod*. 2006;21(3):792-797. doi:10.1093/humrep/dei381
22. Chan YY, Jayaprakasan K, Tan A, Thornton JG, Coomarasamy A, Raine-Fenning NJ. Reproductive outcomes in women with congenital uterine anomalies: a systematic review. *Ultrasound Obstet Gynecol*. 2011;38(4):371-382. doi:10.1002/uog.10056
23. Practice Committee of the American Society for Reproductive Medicine. Uterine septum: a guideline. *Fertil Steril*. 2016;106(3):530-540. doi:10.1016/j.fertnstert.2016.05.014