Journal of Surgical Radiology

Site: https://journalsurgrad.com/

ISSN Print 2156-213X| ISSN Online: 2156-4566 Volume: 03 Issue: 02 Open Access

Research Article

A Cadaveric Study of Histogenesis of Human Fetal Lungs

P. Lakshman Rao[1], M. Sushma[2], Shaik Haseena[3], A. Vasanthi[4]

[1& 2] Associate Professors, Department of Anatomy, AMC, Vishakhapatnam, Andhra Pradesh.

[3]Assistant Professor, Department of Physiology, GMC, Kadapa.

[4]Prof & HOD, Department of Anatomy, DR.YSR GMC, Vizianagaram, Andhra Pradesh.

*Corresponding Author
Dr. M. Sushma

Article History
Received: 14.05.2024
Revised: 30.05.2024
Accepted: 05.06.2024
Published: 27.06.2024

Citations:
Rao, P. L., Sushma, M., Haseena, S., & Vasanthi, A. (n.d.). A cadaveric study of histogenesis of human fetal lungs. J Surg Radiol, V3(2) 33-37

Abstract: ***Introduction:*** Human fetal lung development proceeds through distinct histological stages, and incomplete maturation is a key factor in neonatal respiratory distress, especially in preterm infants. This study conducted to study the histogenesis of human fetal lungs on cadaveric specimens across different gestational ages and to correlate epithelial, mesenchymal and vascular changes with established stages of lung development. **Materials and Methods:** Fifty formalin fixed human fetuses of both sexes, 14–40 weeks gestational age, were obtained from the Obstetrics Department and studied in the Department of Anatomy. Thoracic cavities were opened, lungs were harvested, processed by routine paraffin technique and stained with hematoxylin and eosin (H&E). Fetuses were grouped into three gestational categories (10–20, 20–30, 30–40 weeks); representative lung sections from each group were examined under light microscopy. **Results:** Early gestation (10–20 weeks) showed glandular appearing lungs with compact terminal buds lined by simple columnar epithelium and sparse capillaries in loose mesenchyme. Mid gestation (20–30 weeks) demonstrated widening of lumina, transition to cuboidal epithelium, increasing mesenchymal condensation and marked proliferation of capillaries close to the epithelium. Late gestation (30–40 weeks) revealed terminal sac–like structures with flattened epithelial cells, attenuated cytoplasm, and capillaries closely apposed or exposed to air spaces, with well formed lobular and interlobular connective tissue. **Conclusion:** The study confirms a sequential pattern of epithelial differentiation, mesenchymal remodeling and vascular proliferation in human fetal lungs, consistent with pseudoglandular, canalicular, terminal sac and early alveolar stages, and provides morphologic benchmarks relevant for understanding structural readiness of the lung for extrauterine respiration.

Keywords: Featl Lung, loose mesenchyme, pseudoglandular, canalicular, alveolar stages.

INTRODUCTION

The lungs are vital organs of respiration responsible for oxygenation of blood and removal of carbon dioxide. At birth, the transition from fetus to neonate imposes acute demands on the pulmonary system, as the lung must rapidly convert from a fluid-filled organ with minimal gas exchange to the primary site of gaseous exchange. Successful adaptation requires both physical development of the lung parenchyma and biochemical maturation of the surfactant system.[1,2]

Histologically, human lung development is described as progressing through embryonic, pseudoglandular, canalicular, saccular (terminal sac) and alveolar phases. The respiratory diverticulum appears around 26 days of embryonic life (Carnegie stage 12), arising from foregut endoderm, while surrounding mesenchyme contributes cartilage, smooth muscle, vasculature and connective tissue of the airway wall. Failure of completion of these stages, or premature birth before adequate surfactant production, predisposes the neonate to respiratory distress syndrome (RDS) and other pulmonary complications.[3]

Earlier histogenetic studies have described prenatal lung changes, often focusing on limited gestational windows or specific components such as alveolar epithelium, elastic fibers or vascularization. Loosli and Potter distinguished glandular, canalicular and alveolar periods, later refined into pseudoglandular, canalicular, terminal sac and alveolar stages by Hislop and Reid and subsequent authors. However, many reports are based on relatively small series and emphasize individual features rather than a combined view of epithelial, mesenchymal and vascular changes across a broad gestational spectrum.[4,5,6]

The present cadaveric study attempts to document the histogenesis of human fetal lungs in a series of fetuses from 14 to 40 weeks of gestation, using routine H&E staining and light microscopy, and to correlate the observed changes with established developmental stages and clinical implications for neonatal respiratory adaptation.

This study conducted

- To study the histogenesis of human fetal lungs on cadaveric specimens across defined gestational age groups.
- To describe epithelial differentiation in terminal buds and distal airways (columnar–cuboidal–flattened transitions) during prenatal development.
- To assess mesenchymal changes, including condensation, lobular formation and interlobular connective tissue maturation.

- To document the proliferation and spatial distribution of capillaries in relation to the developing respiratory epithelium and air spaces.
- To correlate histological features with the recognized pseudoglandular, canalicular, terminal sac and early alveolar stages, and to discuss their relevance to neonatal respiratory function.

MATERIALS AND METHODS

Study Design and Setting

This is a descriptive cadaveric histological study conducted in the Department of Anatomy, using human fetuses obtained from the Department of Obstetrics and Gynaecology of a tertiary care teaching hospital. The focus is on qualitative histological features rather than quantitative morphometry.

Sample Size and Selection Criteria

A total of **50** formalin-fixed fetuses of both sexes, with gestational ages between **14** and **40** weeks, were included. Fetuses from multiple pregnancies and those with gross congenital anomalies were excluded, in line with previous organ-weight and lung growth studies. Only fetuses with normal obstetric history and free from detectable external malformations were selected.

Determination of Gestational Age

Gestational age was determined by obstetric history and crown–rump length measurements, as used in prior fetal organ-weight and lung growth analyses. Fetuses were categorized into three gestational groups:

- Group I: **10–20** weeks
- Group II: **20–30** weeks
- Group III: **30–40** weeks

One representative lung tissue block from each age group was selected for detailed histological study.

Fixation and Specimen Preparation

Fetuses were injected with **10%** formalin into pleural, peritoneal and cranial cavities; extremities were preserved by multiple injection techniques. After adequate fixation, the thoracic cavity was opened by disarticulating the sternoclavicular joints and cutting costal cartilages to expose the lungs in situ. The roots of the lungs were dissected at the hilum, and lung specimens were removed and immersed in **10%** formalin.

The lung tissue was processed by standard paraffin-embedding technique. Serial sections were cut and stained with hematoxylin and eosin (H&E) for routine light microscopic examination.

Microscopic Evaluation

Sections were examined under a light microscope to assess:

- Type and arrangement of epithelium in terminal buds, bronchioles and primitive alveolar structures.
- Mesenchymal cellularity, condensation, septal formation and interlobular connective tissue organization.
- Capillary proliferation and distribution within mesenchyme and their proximity to epithelium and air spaces.
- Emergence of lobular architecture and lymphatic channels in interlobular septa.

Histological findings were compared qualitatively across gestational groups and interpreted in relation to classical descriptions of lung development.[7,8]

RESULTS

Group I (10–20 Weeks): Early Pseudoglandular and Canalicular Phases

At gestational ages around **14–20** weeks, the lungs appeared predominantly glandular, composed of numerous epithelial tubules embedded within a loose mesenchymal stroma. Terminal buds were compact and lined by continuous simple columnar epithelium with eosinophilic apical cytoplasm and centrally placed nuclei.

Mesenchymal cells formed one or more layers around the tubules, without marked condensation, and no distinct lobular pattern was evident at the earliest ages. The proximal bronchial tree could be distinguished from terminal buds by irregularly shaped lumina and deeper nuclear staining in the columnar epithelium, with early folds and ciliated cells appearing in some segments.

Capillaries and lymphatics were present in the mesenchyme, but capillary density near the epithelium was modest and variable. Basement membranes around the tubules became more recognizable towards the latter half of this group, suggesting progressive structural organization.

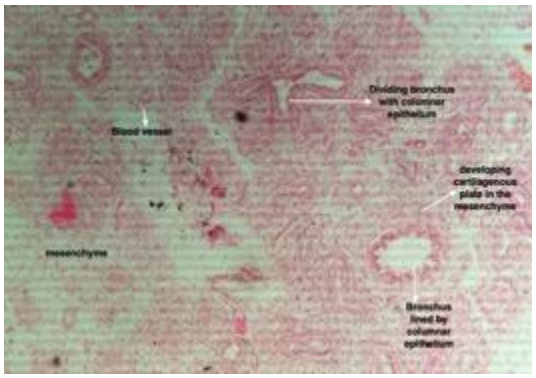

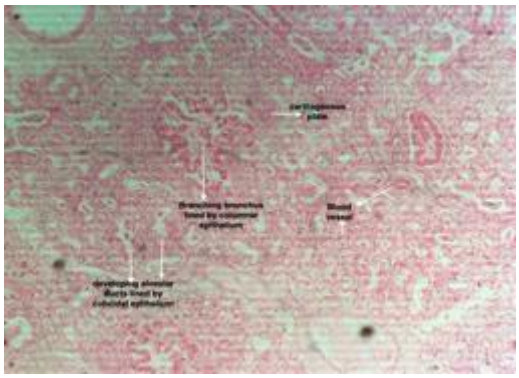

Image 1: 14 wks Image 2: 20 wks
Figure 1a and 1b – Showing Group I (10–20 Weeks): Early Pseudoglandular and Canalicular Phases

Group II (20–30 Weeks): Canalicular to Terminal Sac Transition
Between **20** and **30** weeks, the lung began to lose its purely glandular appearance, and the respiratory portion became more obvious. Many tubules displayed widened, rough-surfaced, irregular lumina lined by low columnar to cuboidal epithelial cells with round vesicular nuclei and clear cytoplasm.

Distal epithelial cells showed a trend towards thinning, with early flattening of nuclei at some sites, reflecting canalicular-stage differentiation towards type I pneumocytes. Proximal tubules displayed irregularly arranged columnar to cuboidal epithelium with deeper-staining nuclei, and bronchi showed well-developed folds, ciliated epithelium and basal cells in certain regions.

Capillary proliferation increased markedly in the mesenchyme adjacent to tubules, with capillaries approaching or invading between epithelial cells in expanded lumina. At these sites, early air–blood barriers were apparent, consistent with canalicular-phase formation of thin gas-exchange interfaces.
Mesenchymal condensation became more pronounced around bronchi and expanded tubules, while interlobular connective tissue showed increasing fibrous organization and reduced cellularity. Lobular architecture became evident as interlobular lymphatics expanded and the interlobular mesenchyme thinned, producing discrete lobular units with differential degrees of luminal expansion—some lobules had many well-expanded lumina, while others appeared collapsed with irregularly arranged epithelial cells.

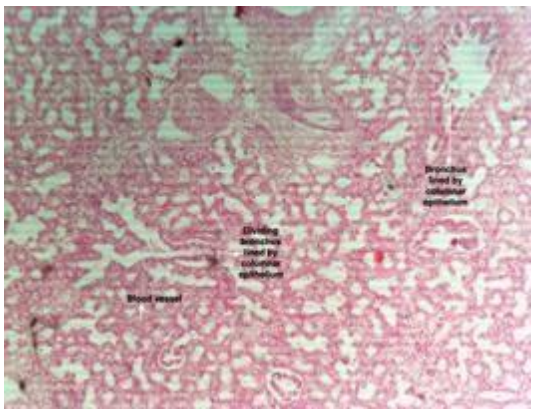

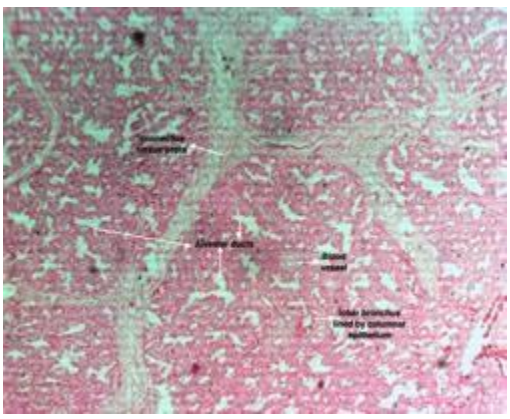

Image 3: 26 wks Image 4: 30 wks
Figure 2a and 2b: Showing Group II (20–30 Weeks): Canalicular to Terminal Sac Transition

Group III (30–40 Weeks): Terminal Sac and Early Alveolar Phases
In fetuses between **30** and **40** weeks, the lung parenchyma displayed features typical of the terminal sac and early alveolar stages. Expanded lumina resembling terminal sacs were lined by a mixture of cells with round vesicular nuclei and flattened dark nuclei; the latter correspond to differentiating type I alveolar epithelial cells.

Attenuated cytoplasmic processes without nuclei projected into luminal spaces, indicating thinning of epithelial cytoplasm and establishment of delicate air–blood interfaces. Capillaries were abundant in the mesenchyme and in many regions lay directly beneath, or between, flattened epithelial cells, forming close endothelial–epithelial contact required for efficient gas exchange.

At some sites, capillaries appeared exposed directly to air spaces, confirming previous descriptions of "naked" capillaries in late fetal lungs that contribute to effective diffusion surfaces. Interlobular connective tissue became distinctly fibrous with fewer cellular elements, and lobules were clearly delineated by compact septa.

The overall pattern showed grape-bunch–like saccules with partially flattened epithelial lining, providing the structural substrate for postnatal alveolar expansion and continued alveolarization in early childhood.

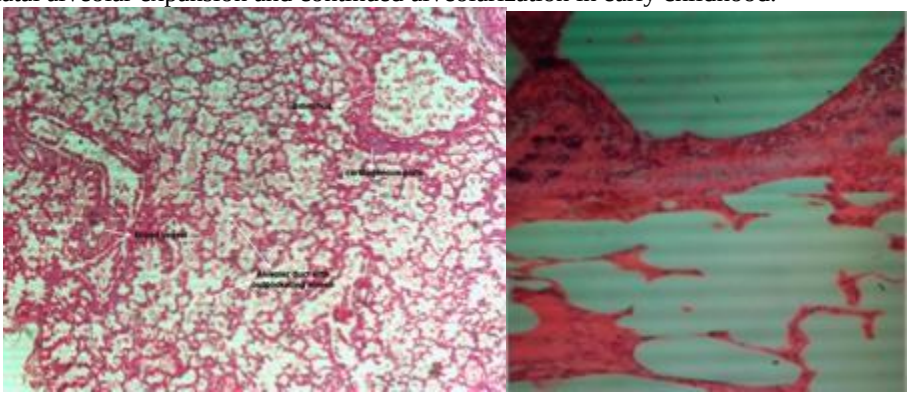

Image 5: 36 wks Image 6: Adult

Figure 3a and 3b: Showing Group III (30–40 Weeks): Terminal Sac and Early Alveolar Phases

Histogenesis and Developmental Correlation

Epithelial Differentiation

The study confirms a progressive epithelial transition in terminal buds and distal tubules: from columnar epithelium in early gestation to low columnar, then cuboidal, and finally flattened epithelial cells in late gestation. This sequence agrees with prior reports that columnar-to-cuboidal change typically occurs around the fifth to early sixth month, followed by flattening associated with the formation of primitive alveoli and terminal sacs.

Differences in nuclear staining between bronchial and respiratory portions were evident—spaces destined to become bronchi showed deeper-staining epithelial nuclei from as early as the fourth month, whereas tubules forming the respiratory portion stained less deeply. This feature aids histologic differentiation between conducting and respiratory segments during development.

Mesenchymal Changes and Lobular Formation

Mesenchymal condensation around bronchi and expanding tubules increased with gestational age, contributing to the development of compact septa and clearer lobular architecture. Interlobular connective tissue evolved from a cellular, loosely arranged matrix to a fibrous stroma with fewer cells, paralleling transitions described between pseudoglandular and terminal sac phases.

The emergence and expansion of interlobular lymphatics accompanied lobular delineation, reflecting maturation of both vascular and lymphatic components of the interstitium. These changes provide the structural framework necessary for efficient fluid balance and mechanical stability of the lung near term.

Vascular Proliferation and Air–Blood Interface

The temporal sequence of capillary proliferation observed in this study corresponds well to classical descriptions: early capillaries scattered in mesenchyme, followed by increased capillary density near epithelium, invasion between epithelial cells, and eventual exposure of capillaries to air spaces by late gestation.

Earlier investigators reported that capillaries begin to push against the epithelium during the fifth to sixth month and naked capillaries become apparent around the seventh month, findings mirrored in the present series. The close apposition of capillaries and flattened alveolar epithelium in late gestation provides the morphologic substrate for effective gas exchange at birth, when alveoli become air-filled and pulmonary blood flow increases.

DISCUSSION

This cadaveric histological study reinforces and extends existing knowledge of human fetal lung histogenesis by correlating epithelial differentiation, mesenchymal remodeling and vascular proliferation across a wide gestational range. The progression from glandular-appearing lungs with compact terminal buds and simple columnar epithelium to lungs with terminal Sac–like structures, flattened epithelial cells and richly vascularized septa closely aligns with the recognized pseudoglandular, canalicular, terminal sac and early alveolar stages.[2,9]

Clinically, understanding these morphologic benchmarks is crucial for managing premature infants, whose structural immaturity and delayed surfactant production predispose them to respiratory distress

syndrome and other forms of neonatal respiratory failure. The demonstration of primitive air–blood barrier formation in mid-gestation and mature epithelial–endothelial contacts by the third trimester explains why extremely preterm infants (before approximately **26–28** weeks) often require intensive respiratory support, whereas near-term and term infants typically possess adequate structural and biochemical maturation for spontaneous respiration.[5,10]

The present findings complement morphometric data indicating that lung weight increases gradually up to around **20** weeks, then rises more steeply between **20** and **24** weeks, with right lung growth slightly exceeding left lung growth later in gestation. Additionally, lung weight–body weight ratios show a complex pattern of early high values, transient falls and later stabilization after approximately **30** weeks, reflecting the interplay between organ growth and overall fetal growth. Together, these histologic and morphometric observations underscore that lung growth and maturation are governed by tightly regulated physical, environmental, hormonal and genetic factors.[7,11]

Limitations

The study is primarily descriptive and employs routine H&E staining without ultrastructural (electron microscopic) or immunohistochemical analysis of surfactant production or specific epithelial cell markers. Representative sampling from gestational groups, rather than systematic examination of all fetuses, may limit detailed analysis of individual variability and precise age-wise quantification of histologic features.

As noted by previous authors, precise localization of observed epithelium within the bronchial tree (bronchi versus bronchioles versus terminal respiratory units) can be challenging in fetal lungs, since tubules destined to become bronchi may lack cartilage and resemble bronchioles. Furthermore, the study does not directly assess biochemical maturation of surfactant, which is known to reach functional maturity around **36** weeks in most fetuses, nor does it relate histologic findings to clinical outcomes such as RDS incidence.

CONCLUSION

In our study concluded that, definitely there's decreasing mesenchyme with increasing fetal age, bronchial branching and alveolar pattern increasing with age and only epithelial changes are yet to be observed. This cadaveric histological study of human fetal lungs demonstrates a coherent sequence of developmental changes in epithelial differentiation, mesenchymal organization and vascular proliferation from early to late gestation. The findings corroborate and refine established descriptions of lung histogenesis and provide morphologic reference points that are valuable for anatomists, pathologists and clinicians dealing with fetal and neonatal respiratory health.

By highlighting the interplay between structural maturation and the surfactant system, the study emphasizes the critical importance of timely lung development for successful transition from fetal to neonatal life and suggests scope for further research using advanced imaging, immunohistochemistry and molecular techniques to link histological maturation with functional respiratory outcomes.

Acknowledgements

We extend my heartfelt gratitude to Dr. A. Vasanthi, Professor and Head, Department of Anatomy, Dr. YSR Government Medical College, Vizianagaram, Andhra Pradesh, whose generous guidance, constant encouragement and kind support have been instrumental in completing this work. Her warm mentorship, inspiring words and unwavering faith in our abilities have touched us deeply, and it has been a privilege to work under her guidance.

REFERENCES

1. Tanaka O, Oki M, Shimatsu A. Histogenetic study on human fetal lungs. Shimane J Med Sci. 1980;4:81–90.
2. Rajkumari A. Growth rate of human fetal lung with increase in gestational age: a morphological study. J Evol Med Dent Sci. 2015;4(34):5827–33.
3. Deepali RK, Sudhir MS. Histogenesis of human fetal lung: a light microscopic study. IOSR J Dent Med Sci. 2013;9(2):1–8.
4. Langston C, Kida K, Reed M, Thurlbeck WM. Human lung growth in late gestation and in the neonate. Am Rev Respir Dis. 1984;129:607–13.
5. Mitropoulos G, Scurry J, Cussen L. Organ weight–body weight ratios and growth rates of fetal organs in the latter half of pregnancy. J Paediatr Child Health. 1992;28(3):236–9.
6. Harding R, Hooper SB. Regulation of lung expansion and lung growth before birth. J Appl Physiol. 1996;81:209–24.
7. Deepali RK, Sudhir MS. Histogenesis of human fetal lung: a light microscopic study. IOSR J Dent Med Sci. 2013;9(2):1–8.
8. Ajmani JB. The principles of embalming techniques in autopsied body. New Delhi: Jaypee Brothers; 1993. p. 131–4.
9. Suchita J, Sailesh K. Lung growth and development. Early Hum Dev. 2007;83:789–94.
10. DiFiore JW, Wilson JM. Lung development. Semin Pediatr Surg. 1994;3:221–32.
11. Whitsett JA, Weaver TE. Hydrophobic surfactant proteins in lung function and disease. N Engl J Med. 2002;347:2141–8.