Journal of Surgical Radiology
Site: https://journalsurgrad.com/

Research Article

DIAGNOSTIC EFFICACY OF MRI FOR EVALUATION OF PERIANAL FISTULA

Dr. Krishna Vora[1], Dr. Virendra Kumar Meena[2], Dr. Ashwani Kumar khandekar[3], Dr. Ravinder Kumar Kundu[4]

[1]Post graduate Resident, Department of Radio-diagnosis, Geetanjali Medical College and Hospital, Geetanjali University, Udaipur, Rajasthan. Email: krivora@gmail.com

[2]Professor, Department of Radio-diagnosis, Geetanjali Medical College and Hospital, Geetanjali University, Udaipur, Rajasthan. Email: virudonvmmc07@gmail.com

[3]Assistant professor, Department of Radiodiagnosis, Geetanjali Medical College & Hospital, Geetanjali University, Udaipur Rajasthan. Email: dr.ashwanikhandekar86@gmail.com

[4]Professor and Head, Department of Radio-diagnosis, Geetanjali Medical College and Hospital, Geetanjali University, Udaipur, Rajasthan. Email: kundu19@yahoo.co.in

*Corresponding Author
Dr. Krishna Vora

Article History
Received: 27.05.2026
Revised: 19.06.2026
Accepted: 25.06.2026
Published: 09.07.2026

Citations:
Vora, K., Meena, V. K., Khandekar, A. K., & Kundu, R. K. (Year). Diagnostic efficacy of MRI for evaluation of perianal fistula. J Surg Radiol, V5 (7) 121-127

Abstract: ***Introduction:*** Perianal fistula is a common anorectal disorder characterized by abnormal communication between the anal canal and perianal skin. Precise preoperative delineation of the fistulous tract and its associated extensions is essential for appropriate surgical planning and prevention of recurrence. Magnetic resonance imaging (MRI) has emerged as the imaging modality of choice because of its excellent soft-tissue contrast and multiplanar imaging capability. **Aim**: To assess the diagnostic efficacy of MRI in the diagnosis and preoperative staging of perianal fistula and to correlate MRI findings with surgical findings. **Materials and Methods**: This time-bound observational (cross-sectional) study was conducted over 18 months in the Department of Radiodiagnosis, Geetanjali Medical College and Hospital, Udaipur. Fifty-five patients with clinically suspected perianal fistula who underwent preoperative MRI followed by surgical management were included. MRI findings regarding fistula classification, internal opening, secondary tracts, abscesses, and supralevator extension were compared with intraoperative findings. Diagnostic indices including sensitivity, specificity, positive predictive value (PPV), negative predictive value (NPV), accuracy, Cohen's kappa, and overall concordance were calculated. **Results**: The mean age of the participants was 46.64 ± 14.64 years, with males constituting 81.8% of the study population. Grade I fistulas were the most common (38.2%), followed by Grade II (27.3%). MRI identified secondary tracts in 21.8%, abscesses in 25.5%, and supralevator extension in 5.5% of patients. The internal opening was successfully detected in 94.5% of cases. MRI demonstrated a sensitivity of 83.3% and specificity of 95.3% for secondary tracts, while overall MRI–surgery concordance was 93.3%. **Conclusion**: MRI is a highly accurate and reliable imaging modality for the evaluation of perianal fistula. Its excellent correlation with surgical findings enables precise anatomical mapping, facilitates optimal surgical planning, improves detection of complex fistulous disease, and may significantly reduce postoperative recurrence and complications. MRI should be considered the preferred preoperative imaging investigation in patients with suspected perianal fistula.

Keywords: Perianal fistula, Magnetic resonance imaging, MRI, Fistula-in-ano, Preoperative evaluation, Diagnostic accuracy, Internal opening, St. James classification.

INTRODUCTION

Perianal fistula is a chronic inflammatory condition characterized by an abnormal epithelialized tract connecting the anal canal to the perianal skin. It commonly develops following cryptoglandular infection of the anal glands, although it may also occur in association with inflammatory bowel disease, particularly Crohn's disease, tuberculosis, trauma, malignancy, radiation injury, or previous anorectal surgery. Patients usually present with recurrent perianal discharge, pain, swelling, abscess formation, and discomfort, leading to considerable impairment in quality of life. The disease is associated with a high rate of recurrence, especially when secondary tracts, internal openings, or occult abscesses remain undetected before surgical intervention. Therefore, accurate preoperative assessment is essential for successful treatment and prevention of recurrence.[1]

The management of perianal fistula primarily depends on precise delineation of the fistulous anatomy. Clinical examination alone is often insufficient because complex fistulas may extend beyond the palpable region, involve multiple secondary tracts, or traverse the anal sphincter complex. Failure to identify these hidden extensions can result in incomplete surgery, persistent infection, fecal incontinence, and repeated operations. Consequently, imaging has become an indispensable component of the diagnostic workup, enabling surgeons to understand the exact course of the fistulous tract and plan sphincter-preserving procedures whenever feasible.[2,3]

Among the available imaging modalities, magnetic resonance imaging (MRI) has emerged as the preferred

technique for evaluating perianal fistulas because of its excellent soft tissue contrast, multiplanar imaging capability, and superior visualization of the anal sphincter complex. Unlike conventional fistulography and computed tomography, MRI provides detailed information regarding the primary tract, internal opening, secondary ramifications, horseshoe extensions, supralevator spread, and associated abscesses without exposing patients to ionizing radiation. High-resolution T2-weighted and fat-suppressed sequences, with or without gadolinium enhancement, further improve tissue characterization and facilitate differentiation between active inflammation and fibrotic changes.[4,5]

Several studies published in recent years have demonstrated the high diagnostic performance of MRI in classifying perianal fistulas according to established systems such as the St. James's University Hospital classification and the Parks classification. MRI findings show excellent agreement with operative findings, thereby assisting surgeons in selecting the most appropriate surgical technique while minimizing damage to the anal sphincters. The ability of MRI to identify clinically occult disease significantly reduces postoperative recurrence and improves long-term functional outcomes. Furthermore, MRI plays an important role in monitoring treatment response, particularly in patients receiving medical therapy for Crohn's-related fistulizing disease.[6–8]

Advances in MRI technology, including three-dimensional imaging, diffusion-weighted imaging, and high-field 3 Tesla MRI, have further enhanced diagnostic accuracy by improving visualization of complex fistulous anatomy and internal openings. Recent evidence also highlights the growing role of standardized MRI reporting and structured radiological assessment in facilitating effective communication between radiologists and colorectal surgeons. These developments have strengthened the role of MRI as the current imaging gold standard for both initial diagnosis and postoperative follow-up of perianal fistulas.[9]

Despite these advancements, variations in MRI interpretation, institutional protocols, and surgical correlation continue to exist. Evaluating the diagnostic efficacy of MRI in different clinical settings remains essential for validating its accuracy and optimizing patient management. Therefore, the present study aims to assess the diagnostic efficacy of MRI in the evaluation of perianal fistula by correlating MRI findings with operative findings and determining its usefulness in identifying fistula type, internal openings, secondary extensions, and associated complications, thereby contributing to improved surgical planning and better patient outcomes.[10]

The present study aims to assess the efficacy of magnetic resonance imaging (MRI) in the diagnosis and preoperative staging of perianal fistula, facilitating optimal surgical planning while minimizing recurrence and postoperative complications. The study also seeks to evaluate the type of fistula based on the location of the internal opening and the presence or absence of associated abscesses, and to correlate preoperative MRI findings with intraoperative surgical findings to determine the diagnostic accuracy of MRI in the evaluation of perianal fistula.

MATERIALS AND METHODS

Study Design: Time-bound observational (cross-sectional) study.

Study Population: All patients of either sex and all age groups with clinically suspected or diagnosed perianal fistula who were referred to the Department of Radiodiagnosis for MRI evaluation and subsequently underwent surgical management.

Sample Size: A total of 55 consecutive patients fulfilling the inclusion criteria were enrolled during the study period.

Study Duration: 18 months.

Study Place: Department of Radiodiagnosis, Geetanjali Medical College and Hospital (GMCH), Udaipur, Rajasthan, India, equipped with a 3-Tesla SIGNA ARCHITECT MRI system (GE Healthcare).

Inclusion Criteria:

- Patients clinically suspected or diagnosed with perianal fistula and evaluated by MRI.
- Patients willing to provide written informed consent.

Exclusion Criteria:

- Patients with contraindications to MRI (e.g., cardiac pacemakers, metallic implants, aneurysmal clips, etc.).
- Patients with fistulas secondary to Crohn's disease, rectal carcinoma, congenital fistula, or previous pelvic radiation therapy.
- Patients unwilling to provide written informed consent.

Statistical Analysis

The collected data were entered into Microsoft Excel and analyzed using Statistical Package for the Social Sciences (SPSS) software version 26.0 (IBM Corp., Armonk, NY, USA). Continuous variables were expressed as mean ± standard deviation (SD), while categorical variables were presented as frequency and percentage. The association between categorical variables was assessed using the Chi-square test or Fisher’s exact test, as appropriate. A p-value <0.05 was considered statistically significant. Surgical findings served as the gold standard for comparison. The diagnostic performance of MRI was evaluated by calculating sensitivity, specificity, positive predictive value (PPV), negative predictive value (NPV), and overall diagnostic accuracy. Agreement between MRI findings and surgical findings was assessed using Cohen’s kappa (κ) coefficient, and diagnostic

discrimination was evaluated using the area under the receiver operating characteristic (ROC) curve (AUC).

RESULTS

Table 1. Baseline Characteristics of the Study Participants

Variable	Category	n	%
Age Group (years)	≤20	1	1.8
	21–30	7	12.7
	31–40	15	27.3
	41–50	8	14.5
	51–60	13	23.6
	>60	11	20
Sex	Male	45	81.8
	Female	10	18.2
Comorbidity	None	30	54.5
	Diabetes mellitus	8	14.5
	Hypertension	6	10.9
	Tobacco use	5	9.1
	DM + HTN	2	3.6
	Carcinoma	2	3.6
	Trauma	1	1.8
	Recurrent fistula	1	1.8
Mean age		**46.64 ± 14.64 years**	
Male:Female		**4.5:1**	

Table 2. MRI Characteristics and Classification of Perianal Fistula

Variable	Category	n	%
Surgical Diagnosis	Fistula in ano	38	69.1
	Fistula with abscess	14	25.5
	Recurrent fistula	3	5.5
St. James Grade	Grade I	21	38.2
	Grade II	15	27.3
	Grade III	10	18.2
	Grade IV	7	12.7
	Grade V	2	3.6
MRI Findings	Secondary tract	12	21.8
	Abscess	14	25.5
	Supralevator extension	3	5.5
	Multiple external opening	1	1.8

Table 3. MRI Localization of Fistulous Openings (N=55)

Variable	Category	n	%
Internal Opening Region	Posterior	32	58.2
	Anterior	12	21.8
	Lateral	8	14.5
	Not detected	3	5.5
External Opening	Left of natal cleft	17	30.9
	Right of natal cleft	7	12.7
	Midline	4	7.3
	Other positions	24	43.6
	Not detected	3	5.5
Internal Opening Detection	MRI detected	52	94.5
	MRI not detected	3	5.5

Table 4. Diagnostic Performance of MRI Compared with Surgery

MRI Finding	Sensitivity (%)	Specificity (%)	PPV (%)	NPV (%)	Accuracy (%)	Cohen's κ	AUC
Secondary tract	83.3	95.3	83.3	95.3	92.7	0.787	0.893
Abscess	80	95	85.7	92.7	90.9	0.766	0.875
Supralevator extension	66.7	98.1	66.7	98.1	96.4	0.647	0.824
Internal opening*	—	—	—	—	94.5	—	—

Table 5. Overall MRI–Surgery Agreement

Parameter	Value
Total assessments	165
Concordant	154
Discordant	11
Overall concordance	93.30%

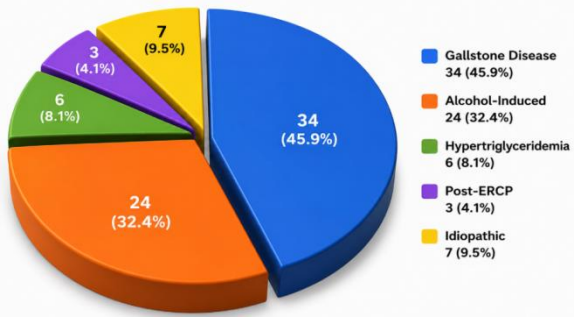

Figure: 1.Comorbidityof the Study Participants

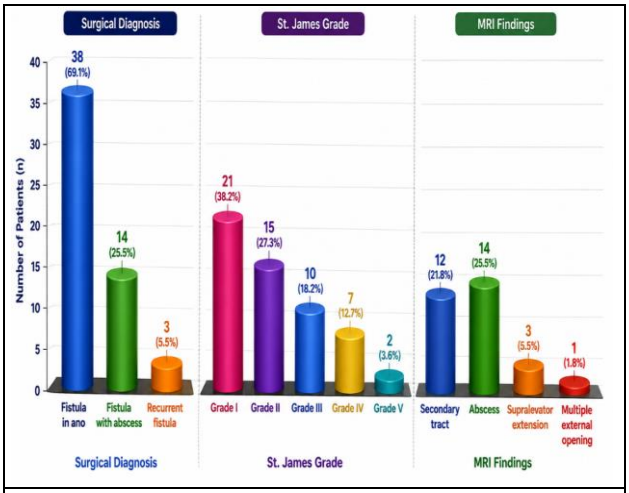

Figure: 2.MRI Characteristics and Classification of Perianal Fistula

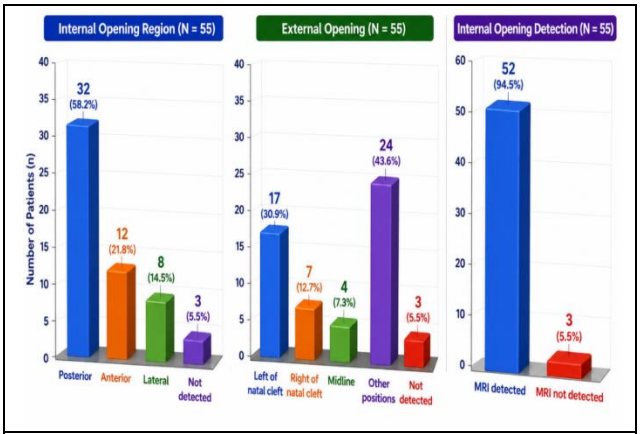

Figure: 3.MRI Localization of Fistulous Openings

A total of 55 patients with clinically suspected perianal fistula were included in the study. The mean age of the study population was 46.64 ± 14.64 years. The largest proportion of patients belonged to the 31–40 years age group (15 patients; 27.3%), followed by 51–60 years (13; 23.6%) and >60 years (11; 20.0%). Patients aged 41–50 years accounted for 8 (14.5%), while 21–30 years comprised 7 (12.7%). Only 1 patient (1.8%) was aged 20 years or younger. Male patients predominated, with 45 (81.8%) males and 10 (18.2%) females, yielding a male-to-female ratio of 4.5:1. Regarding associated comorbidities, the majority of participants (30; 54.5%) had no underlying medical illness. Among those with comorbid conditions, diabetes mellitus was the most common, affecting 8 patients (14.5%), followed by hypertension in 6 (10.9%) and tobacco use in 5 (9.1%). Combined diabetes mellitus and hypertension, carcinoma, trauma, and recurrent fistula were less frequent, accounting for 2 (3.6%), 2 (3.6%), 1 (1.8%), and 1 (1.8%) patients, respectively.

MRI evaluation demonstrated that 38 patients (69.1%) had uncomplicated fistula-in-ano, whereas 14 patients (25.5%) had fistula associated with abscess formation, and 3 patients (5.5%) presented with recurrent fistula. According to the St. James University Hospital MRI classification, Grade I fistulas were the most common, observed in 21 patients (38.2%), followed by Grade II in 15 patients (27.3%). More advanced disease was less common, with Grade III identified in 10 patients (18.2%), Grade IV in 7 patients (12.7%), and Grade V in only 2 patients (3.6%). MRI also identified important associated pathological findings, including secondary fistulous tracts in 12 patients (21.8%), abscesses in 14 patients (25.5%), supralevator extension in 3 patients (5.5%), and multiple external openings in 1 patient (1.8%).

MRI successfully localized the internal opening in the majority of patients. The posterior internal opening was the most frequent location, identified in 32 patients (58.2%), followed by the anterior region in 12 patients (21.8%) and the lateral region in 8 patients (14.5%). In 3 patients (5.5%), the internal opening could not be detected on MRI. Regarding the external opening, the highest proportion was located at other perianal positions (24 patients; 43.6%), followed by the left side of the natal cleft in 17 patients (30.9%), the right side in 7 patients (12.7%), and the midline in 4 patients (7.3%). MRI successfully detected the internal opening in 52 of 55 patients (94.5%), while it failed to identify the opening in only 3 patients (5.5%), demonstrating a high detection rate.

The association between clinicodemographic variables and fistula complexity (simple Grade I–II versus complex Grade III–V) was analyzed using the Chi-square/Fisher's exact test. No statistically significant association was observed between age group and fistula complexity ($p = 0.597$). Similarly, sex showed no significant relationship with disease complexity ($p = 1.000$). Analysis of comorbid conditions also revealed no statistically significant association, with 19 patients with simple fistula versus 17 with complex fistula among one category and 11 versus 8 patients, respectively, in another category ($p = 0.781$). These findings suggest that patient age, gender, and comorbidity status did not significantly influence MRI-based fistula complexity in the present study.

MRI demonstrated excellent diagnostic performance when compared with operative findings. For identifying secondary fistulous tracts, MRI achieved a sensitivity of 83.3%, specificity of 95.3%, positive predictive value (PPV) of 83.3%, negative predictive value (NPV) of 95.3%, and an overall diagnostic accuracy of 92.7%. The agreement with surgery was substantial, with a Cohen's kappa value of 0.787, while the area under the ROC curve (AUC) was 0.893.

For abscess detection, MRI demonstrated a sensitivity of 80.0%, specificity of 95.0%, PPV of 85.7%, NPV of 92.7%, and an overall accuracy of 90.9%. The agreement with surgical findings remained substantial ($\kappa = 0.766$), with an AUC of 0.875.

MRI also performed well in identifying supralevator extension, showing a sensitivity of 66.7%, specificity of 98.1%, PPV of 66.7%, NPV of 98.1%, and an overall accuracy of 96.4%. Although sensitivity was relatively lower due to the limited number of cases, specificity remained exceptionally high. The level of agreement with surgery was substantial ($\kappa = 0.647$), with an AUC of 0.824. Furthermore, MRI detected the internal opening in 94.5% of patients, highlighting its excellent capability in preoperative localization.

Overall comparison between MRI findings and operative findings demonstrated excellent concordance. A total of 165 individual assessments were performed, of which 154 (93.3%) were concordant, while only 11 (6.7%) showed discordance. The overall concordance rate of 93.3% indicates a high level of agreement between MRI and surgical findings, confirming the reliability of MRI as an accurate preoperative imaging modality for evaluating perianal fistula anatomy and associated complications.

IMAGES

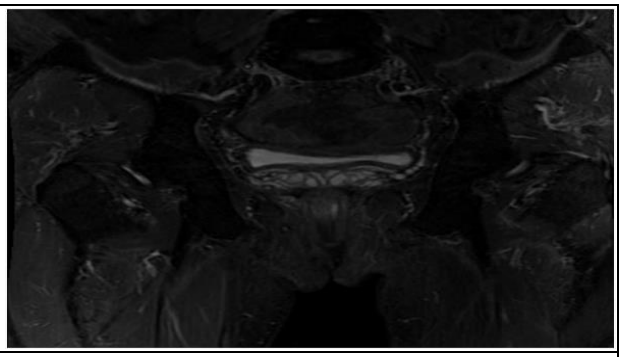

Image 1: Grade 1 fistula inano

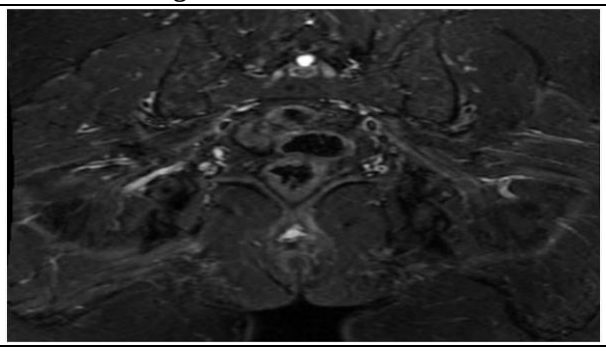

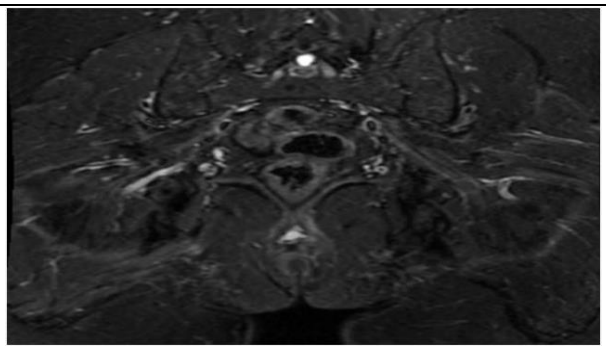

Image2: Grade 2 fistula with abscess







Image 3: Grade 3 fistula inano





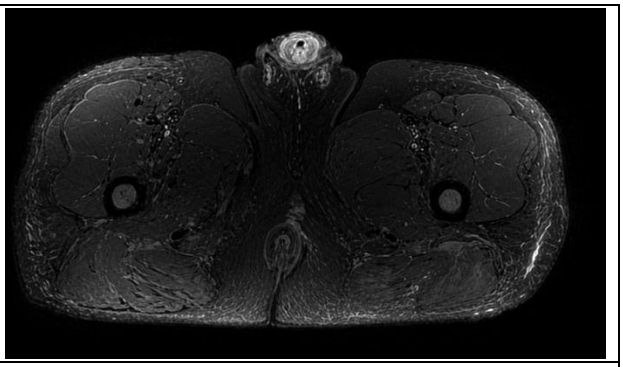

Image 4: Grade 4 fistula inano

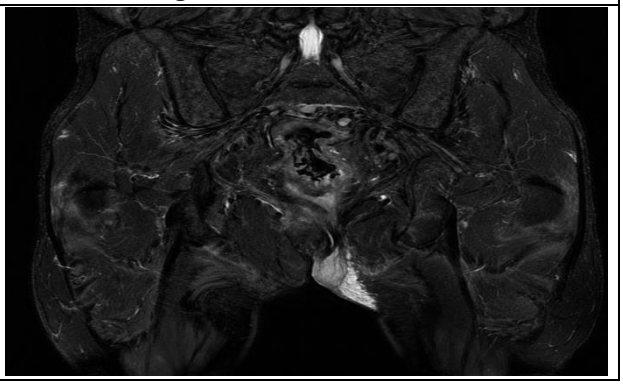



Image 5: Grade 5 fistula inano [supralevator extension]

DISCUSSION

The present study included 55 patients with clinically suspected perianal fistula who underwent preoperative MRI followed by surgical exploration. The mean age of the study population was 46.64 ± 14.64 years, with the highest proportion of patients belonging to the 31–40 years age group (27.3%). Male predominance (81.8%) with a male-to-female ratio of 4.5:1 was observed, indicating that perianal fistula is considerably more common among men. Similar demographic findings have been reported by Zabit et al., who observed a mean age of approximately 43 years with a predominance of male patients, and by Ali et al., who also reported that nearly four-fifths of patients with fistula-in-ano were men. These findings support the established epidemiological pattern that cryptoglandular fistulas occur predominantly in middle-aged males, possibly because of anatomical and hormonal factors influencing anal gland infections and fistula formation. The relatively high proportion of patients without significant comorbidities (54.5%) in the present study is also consistent with previous reports showing that most fistulas occur in otherwise healthy individuals, although diabetes mellitus may contribute to delayed healing and recurrent disease.[11,12]

MRI classification in the present study demonstrated that Grade I fistulas (38.2%) were the most frequent, followed by Grade II lesions (27.3%), whereas complex Grade III–V fistulas constituted a smaller proportion. These findings indicate that simple intersphincteric disease remains the commonest presentation in routine clinical practice. Comparable observations have been reported by Narra et al., who found uncomplicated fistulas to be the predominant MRI pattern, while complex fistulas represented a smaller but clinically important subgroup requiring detailed preoperative mapping. Likewise, recent reviews emphasize that MRI-based St. James classification accurately reflects disease severity and assists surgeons in selecting sphincter-preserving procedures according to fistula complexity.[13,14]

The present study demonstrated that MRI detected secondary tracts in 21.8% of patients, abscesses in 25.5%, and supralevator extension in 5.5%. Identification of these associated abnormalities is essential because missed extensions remain one of the major causes of postoperative recurrence. Similar findings were reported by Sankaran et al., who demonstrated excellent MRI performance in identifying secondary tracts and abscesses with high agreement with surgical findings. Arkenbosch et al. further highlighted that MRI provides excellent visualization of occult abscesses, horseshoe extensions, and supralevator disease, which may not be appreciated during clinical examination alone. These observations reinforce the value of MRI in comprehensive preoperative assessment of complex fistulous disease.[15,16]

With regard to localization of fistulous openings, posterior internal openings were the most common (58.2%), and MRI successfully detected internal openings in 94.5% of patients. Accurate localization of the internal opening is one of the most important determinants of successful surgical management because failure to identify the internal opening increases the risk of recurrence. Similar detection rates have been described by recent studies evaluating MR fistulography, which demonstrated high sensitivity and excellent agreement with operative findings for localization of both internal and external openings. Structured MRI reporting has also been shown to improve communication between radiologists and colorectal surgeons, thereby facilitating more accurate operative planning.[17,18]

No statistically significant association was observed between fistula complexity and age, sex, or associated comorbidities in the present study ($p>0.05$). These findings suggest that although demographic characteristics influence disease occurrence, they do not necessarily predict MRI-defined anatomical complexity. Similar observations have been reported in recent clinical studies, where fistula morphology was found to depend more on the anatomical course of the tract and chronic inflammatory changes than on baseline patient characteristics. Current evidence therefore supports detailed MRI evaluation for every patient irrespective of demographic profile.[14,19]

MRI demonstrated excellent diagnostic performance in comparison with operative findings. The sensitivity and specificity for detecting secondary tracts were 83.3% and 95.3%, respectively, while abscess detection showed sensitivity of 80.0% and specificity of 95.0%. Supralevator extension demonstrated very high specificity (98.1%), and the overall internal opening detection rate reached 94.5%. Overall MRI–surgery concordance was 93.3%, confirming excellent agreement. These findings closely parallel those reported by Zabit et al., who demonstrated overall MRI diagnostic accuracy exceeding 95%, and by recent retrospective studies reporting sensitivities above 90% with excellent correlation between MRI and operative findings. Modern 3-Tesla MRI, together with standardized reporting protocols, therefore remains the

imaging modality of choice for preoperative evaluation of perianal fistula because it provides accurate delineation of fistulous anatomy while reducing recurrence resulting from missed tracts or occult abscesses.[11,20]

CONCLUSION

The present study demonstrates that magnetic resonance imaging is a highly reliable and accurate imaging modality for the preoperative evaluation of perianal fistula. MRI provided excellent visualization of the primary fistulous tract, internal opening, secondary extensions, abscesses, and supralevator involvement, with a high overall concordance of 93.3% when compared with surgical findings. The high sensitivity, specificity, and diagnostic accuracy observed for major fistula characteristics confirm the value of MRI in comprehensive anatomical mapping before surgery. Accurate preoperative assessment facilitates appropriate surgical planning, enables sphincter-preserving procedures whenever feasible, and reduces the likelihood of missed tracts, postoperative recurrence, and complications. Although demographic and clinical variables were not significantly associated with fistula complexity, MRI consistently provided detailed anatomical information irrespective of patient characteristics. Therefore, MRI should be considered the imaging modality of choice in all patients with suspected or complex perianal fistula, particularly before definitive surgical intervention, to improve operative outcomes and long-term patient prognosis.

REFERENCES

1. Gecse KB, Bemelman W, Kamm MA, et al. World Gastroenterology Organisation Global Guidelines: Perianal fistulizing disease. *J Clin Med*. 2020;9(11):3560.
2. Halligan S, Stoker J. Imaging of fistula-in-ano: recent advances and future directions. *Br J Radiol*. 2021;94(1124):20210148.
3. Panés J, Rimola J. Perianal fistulizing Crohn's disease: imaging and management update. *Nat Rev Gastroenterol Hepatol*. 2021;18(1):7-20.
4. Aly RA, El Sayed AA, Mohamed MA. Role of MRI in classification and preoperative evaluation of perianal fistulas. *Egypt J Radiol Nucl Med*. 2024;55:145.
5. Arkenbosch JHC, Stoker J, Felt-Bersma RJF, et al. The role of MRI in perianal fistulizing disease. *Abdom Radiol (NY)*. 2025;50:193-206.
6. Abdulla KV, Chandran S, Nair S, et al. Comparison of contrast-enhanced three-dimensional imaging with two-dimensional MRI sequences in evaluation of perianal fistulas. *Indian J Radiol Imaging*. 2023;33(4):620-628.
7. Habeeb H, Tozer PJ, Hart AL. Imaging in perianal fistulising Crohn's disease. *World J Gastroenterol*. 2025;31:100945.
8. Khanduri S, Gupta A, Sharma R, et al. Seeing beyond the tract: the superiority of 3 Tesla MRI in evaluation of perianal fistula. *Cureus*. 2025;17:e78934.
9. Neves PO, Rocha EL, Oliveira MA, et al. Using MRI to guide surgical strategy for perianal fistulas. *Radiol Bras*. 2026;59(1):e20250045.
10. Zimmerman DDE, Felt-Bersma RJF, Bemelman WA, et al. Structured magnetic resonance imaging reporting for cryptoglandular anal fistulas. *World J Gastroenterol*. 2024;30:5853-5865.
11. Zabit F, Khan MA, Ahmed A, et al. Diagnostic accuracy of magnetic resonance imaging for perianal fistula assessment using operative findings as the gold standard. *Pak J Pathol*. 2024;35(3):120-126.
12. Ali H, Khan M, Ahmed S, et al. Magnetic resonance imaging in detection of perianal fistula. *Pak J Health Sci*. 2022;3(5):209-213.
13. Narra R, Reddy S, Kumar P, et al. Role of magnetic resonance imaging in evaluation of perianal fistula. *J Dr NTR Univ Health Sci*. 2024;13(3):146-152.
14. Arkenbosch JHC, Stoker J. The role of MRI in perianal fistulizing disease: diagnostic and therapeutic implications. *Abdom Radiol (NY)*. 2025;50:193-206.
15. Sankaran R, Prakash S, Kumar V, et al. The role of MRI diagnostic accuracy in evaluating perianal fistulas and its correlation with surgical findings. *Int J Med Pharm Res*. 2026;11(2):115-123.
16. Kumar A, Singh R, Sharma V, et al. Diagnostic accuracy of MR fistulogram in the evaluation of perianal fistulas: correlation with surgical findings. *Int J Med Pharm Res*. 2025;10(4):210-218.
17. Ahmed S, Hussain M, Fatima N, et al. Diagnostic accuracy and clinical effectiveness of MRI in evaluating perianal fistula: comparison with surgical findings. *J Clin Diagn Res*. 2025;19(1):TC01-TC06.
18. Argın V, Demir A, Kaya M, et al. MRI accuracy and outcomes in perianal fistula surgery: a retrospective study. *Med Sci Discov*. 2025;12(4):301-309.
19. Garg P. Recent advances in the diagnosis and management of cryptoglandular anal fistula. *World J Gastrointest Surg*. 2022;14(10):1152-1168.
20. Singh K, Verma A, Meena R, et al. Preoperative MRI assessment of fistula-in-ano and its correlation with operative findings in a tertiary care centre. *Cureus*. 2026;18:e91234.